

## Breast Cancer Detection Utilizing Biostereometric Analysis

C. W. Loughry  
D. B. Sheffer  
R. H. Hamor  
R. E. Herron

R. A. Liebelt  
F. Proietti-Orlandi  
R. S. Varga

*Departments of Surgery (C.W.L.) and Radiology (R.H.H.), and Biostereometrics Laboratory (D.B.S.), Akron City Hospital, Akron, OH; Institute for Biomedical Engineering, University of Akron, Akron, OH (R.E.H., D.B.S.); Northeastern Ohio Universities, College of Medicine, Rootstown, OH (R.A.L.); and Department of Mathematics, Kent State University, Kent, OH (F.P.-O., R.S.V.)*

---

**ABSTRACT** Twelve female patients participated in a study designed to employ computer-assisted biostereometric analysis for the detection of breast masses. All breast masses were previously documented by physical examination and followed by xeromammography, stereophotography, and histopathologic confirmation of tumor type. "Contour mammograms" were produced from the biostereometric photographs. These data were analyzed first for tumor detection and location by visual inspection. A second analysis employed a computed algorithm designed to locate and measure surface aberrations that suggest the possibility of underlying breast tumor. Visual analysis yielded the exact location of breast tumors in eight of the ten malignancies; computer analysis exactly located nine of the ten malignancies. In the computer analysis, one malignancy not exactly located by quadrant was, nevertheless, located in the correct breast. The results of the study suggest that the biostereometric process may have future use in screening or prescreening procedures for breast cancer detection. It is noninvasive, applicable to large numbers of women and with suitable refinements, and capable of being fully automated.

**Key words:** biostereometric analysis, detection of breast masses, computerized, screening process

### INTRODUCTION

An ideal method of breast cancer screening has yet to be developed. Such a method should be reliable, harmless, inexpensive, applicable to a large number of women,\* and simple, thus reducing or eliminating more cumbersome forms of screening currently in use, such as breast self-examination, yearly physical examination by a physician, and xeromammography. To be maximally

\*The U.S. census of 1970 reported 39,810,880 women over the age of 35 living in the United States.

useful, such a method might not even have to locate tumors specifically, but instead merely detect a difference between breast size and formation, or a change in breast configuration over a given period of time. In this context, the method might be termed a prescreening process, useful in identifying those individuals for whom more elaborate study, as in physical examination by a physician and/or mammography, is indicated.

A potential methodology had been demonstrated in an earlier study, by Liebelt and Herron [1], in which the biostereometric process had proved precise enough to document volume distribution changes in the human breast during the menstrual cycle and locate within the breast the site of such changes.

Loughry et al [2] recently reported on a new method of breast cancer detection through biostereometric analysis in which "contour mammograms" produced by the biostereometric process were visually examined for abnormal patterns indicating potential underlying breast pathology. Utilizing this method they were able to detect the cancer and its correct location in eight out of ten cases, with tumors ranging in size from 1 cm to 4.5 cm in diameter. Five of the eight cancers detected by this method were not visible during the physical examination of the breast.

Having recognized the potential subjectivity of the visual evaluation of the contour mammogram, Loughry et al further examined in the current study the same biostereometric information, using a computer algorithm designed to detect breast tumors more objectively.

### METHODOLOGY

Twelve female subjects, ranging in age from 45 to 76, participated in this study. Each was examined for known breast masses, and estimated sizes and locations of palpable tumors were noted. In each of the twelve cases, clinical examination was followed by xeromammography, stereophotography, and surgery or cyst aspiration for pathologic confirmation.

#### Stereophotography

Collection of data for the biostereometric analysis of breast surface contours required the use of one pair of modified Hasselblad superwide angle C cameras to photograph patients stereometr-

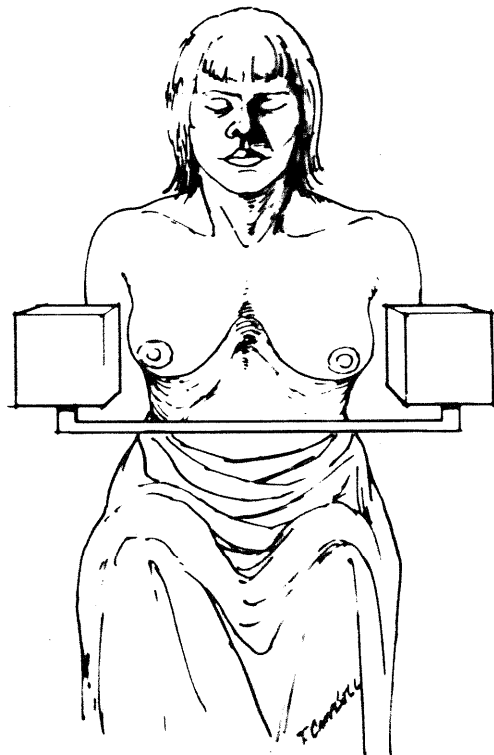


Fig. 1. Subject-stereocamera relationship for seated position.

ically, first in a sitting position (Fig. 1) and then in a bending posture with the breasts dependent (Fig. 2). Photographs obtained were then reduced to Cartesian coordinates on a Kern PG-2 stereoplotter linked to a DEC PDP 11/70 computer. These coordinates yielded contour mammograms (Fig. 3) which were subjected to visual and computer analysis for surface aberrations or deviations.



Fig. 2. Subject-stereocamera relationship for bending position.

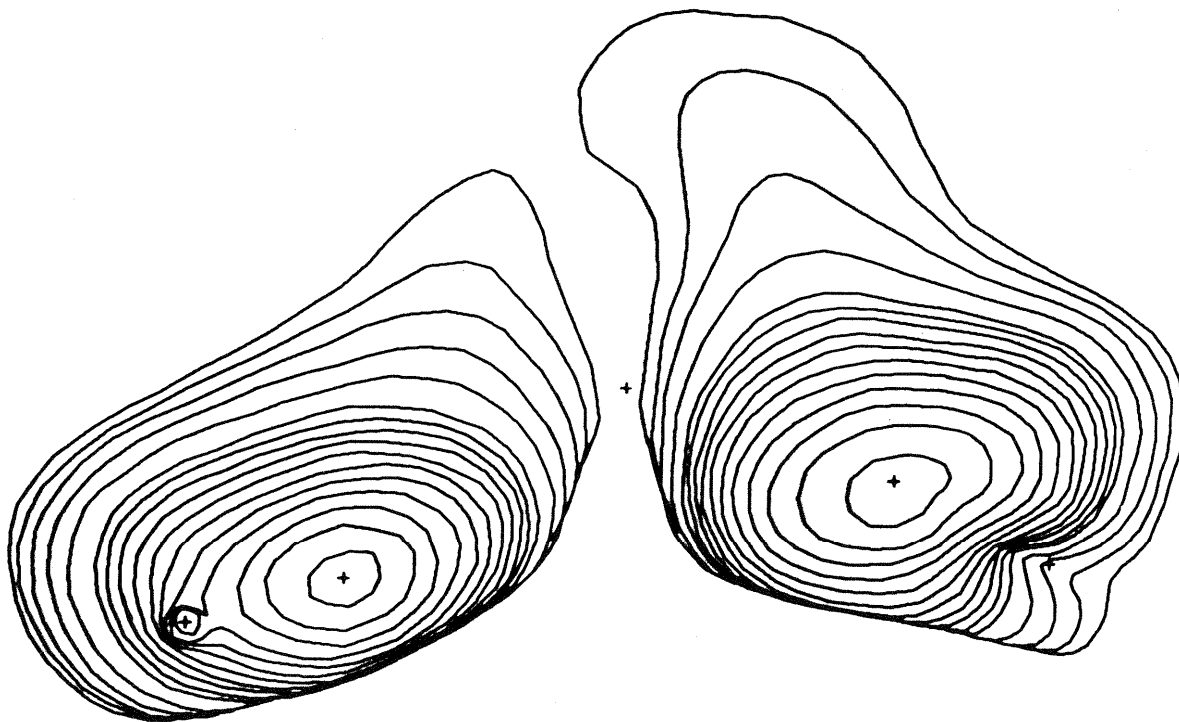


Fig. 3. A contour mammogram of a patient with a 4.5-cm infiltrating ductal carcinoma. Note indentation of contour lines in lower outer quadrant of left breast.

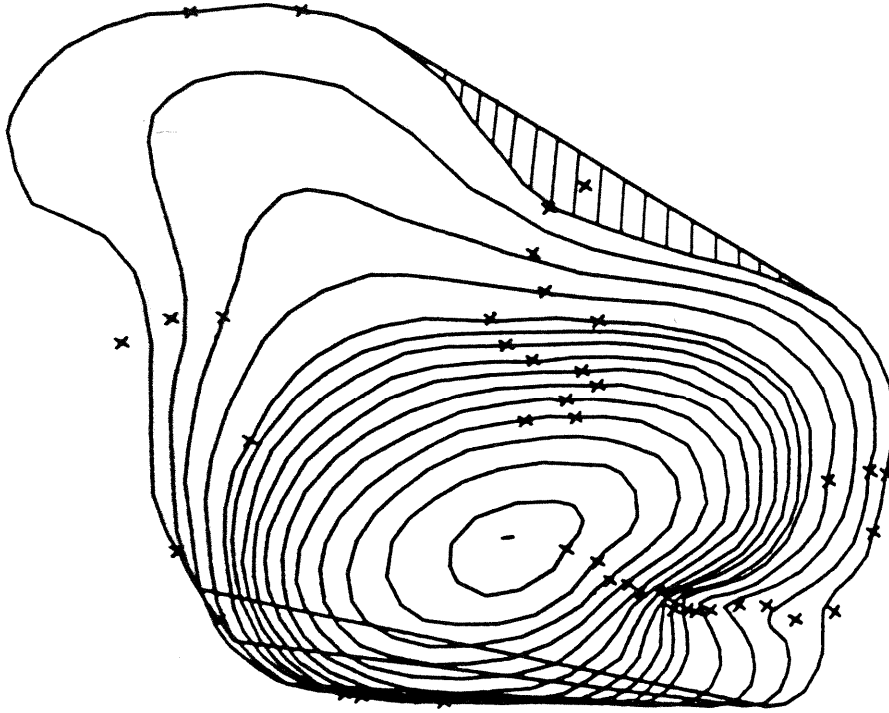


Fig. 4. For each level curve, the convex hull is determined, and any departure of the original level curve from the boundary of its convex hull defines an area of concavity (shaded area represents one such concave area). Here the center of gravity of each concave area is marked with the symbol "X."

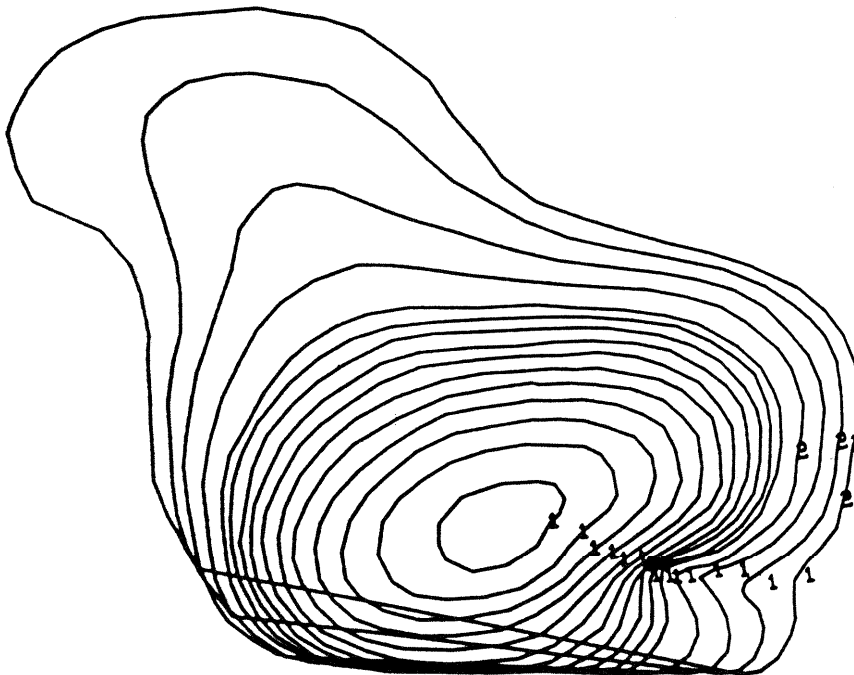


Fig. 5. The final two classes identified by the iterative process. The concavities of the first type (1) correlate with cancer in the breast.

### Biostereometric Analysis

No information regarding the results of the clinical or mammographic examinations was revealed to the members of the research team performing the biostereometric analysis. Two separate approaches for this analysis were adopted. In the first, attempts were made to identify an existing lesion and its quadrant by visual inspection for deviations or distortions of the contour lines.

Because surface aberrations of the breast might not be detected by visual inspection alone, a second analysis was performed. In this second analysis, biostereometric photographs were subjected to computer techniques designed for locating, measuring, and classifying the breast aberrations.

The algorithm consisted primarily of defining the convex hull of each digitized level curve of the breast. Any departure of the original level curve from the boundary of its convex hull defined an area of concavity (Fig. 4). Through an iterative cluster analysis technique, the areas of concavity were grouped into subclasses until a pattern of concavities became apparent. The final emergent pattern (Fig. 5) was designated as an area of suspicion, suggesting the possibility of an underlying breast tumor. Correlations were then carried out between the clinical findings, xeromammography, histopathologic diagnoses, and the two biostereometric analyses.

### RESULTS

All twelve patients had positive clinical findings of breast pathology, a prerequisite for inclusion in this study. Similarly, all twelve patients had positive xeromammographic findings. Histopathologic diagnoses revealed that ten of the twelve patients had malignant neoplasms ranging in size from 1 cm in diameter to a maximum of 4.5 cm, with a mean size of 2.2 cm. In the remaining two patients, benign cysts were found, one measuring 4.0 cm and the other 2.5 cm. Eight of the malignant lesions were diagnosed as infiltrating ductal carcinomas, and two as medullary carcinomas.

Visual biostereometric analysis correctly determined the presence and location of malignant tumors in 80% of the cases, as previously reported [1] and depicted in Figure 6. Computer-assisted analysis resulted in detection of the exact location of the tumors in nine of the ten cases with malignant lesions. In the tenth case (Subject 13), the correct breast was identified but not the exact location of the tumor. In one additional case, analysis yielded a false-positive. In this case (Subject 2), a lesion was diagnosed in the second breast that was not documented by clinical or xeromammographic examination. Computer-assisted analysis also correctly identified the breast and exact location of one of the two benign tumors found in the study.

### DISCUSSION

A pilot study utilizing biostereometric analysis was undertaken in an effort to assist in the search for a better means of screening for breast cancer or selecting those women for whom further investigation of breast abnormalities is indicated.

Twelve women with documented breast masses participated in the study. Of the twelve subjects, ten were diagnosed as having malignant tumors, and two as having benign cysts. Of the ten malignant tumors, only three were visible by physical examination to the unaided human eye. Of the benign masses, none was visible.

The study involved two systems of blind analysis. In the first, visual examination and interpretation of contour mammographs was employed; in the second, the same data were subjected to computer analysis.

Visual analysis yielded exact knowledge of tumor location in eight of the ten malignancies; computer analysis exactly located nine out of ten malignancies. In the computer analysis, the one malignancy not exactly located by quadrant was, nevertheless, located in the correct breast. Additionally, the computer analysis yielded one false-positive.

Data gathered in this pilot study indicate that biostereometric analysis can provide useful information about the physiology, anatomy, and pathology of the female breast. It also suggests

| SUBMIT<br>ID<br>NO. | CLINICAL | VISUAL<br>STEREOMETRIC | COMPUTED<br>STEREOMETRIC |
|---------------------|----------|------------------------|--------------------------|
| 2                   |          |                        |                          |
| 4                   |          |                        |                          |
| 7                   |          |                        |                          |
| 8                   |          |                        |                          |
| 10                  |          |                        |                          |
| 11                  |          |                        |                          |
| 12                  |          |                        |                          |
| 13                  |          |                        |                          |
| 14                  |          |                        |                          |
| 15                  |          |                        |                          |
| 16                  |          |                        |                          |
| 17                  |          |                        |                          |

= LOCATED  
 = MISSED  
 = FALSE POSITIVE  
 = BENIGN

Fig. 6. Graphic summarization of breast cancer detection utilizing biostereometric visual and computer-assisted analysis.

that the biostereometric process may have future use in screening or prescreening procedures for breast cancer. It is noninvasive, applicable to large numbers of women, and capable of being fully automated.

The results of this project seem to its investigators to justify further study of the accuracy of biostereometric analysis in differentiating between normal and pathologic breasts.

#### ACKNOWLEDGMENTS

The authors would like to acknowledge the help of Valory Murray, PhD, Grants Coordinator, Akron City Hospital, in the preparation of this manuscript.

#### REFERENCES

1. Liebelt RA, Herron RE. Stereometric analysis in the field of anatomy. In Herron RE (ed): Proc Sem Quantitative Imagery in the Biomedical Sciences, Houston, May 1971. Proc Soc Photo-Optical Instrum Engrs 1972;26:000-000.
2. Loughry CW, Liebelt RA, Herron RE, Hamor RH, Liebelt AG, Cuzzi J. Detection of breast cancer utilizing biostereometric analysis: A preliminary report. Breast Dis Breast 1980;6:11-15.